Persistence of dysmenorrhea and nonmenstrual pain after optimal endometriosis surgery may indicate adenomyosis

Jason D. Parker, D.O.,[a,b,c] *Mark Leondires, M.D.,*[a,b,c,d] *Ninet Sinaii, M.P.H.,*[b] *Ahalya Premkumar, M.D.,*[e] *Lynnette K. Nieman, M.D.,*[a,b] *and Pamela Stratton, M.D.,*[a,b]

[a] Combined Federal Fellowship in Reproductive Endocrinology and Infertility at National Institutes of Health, Walter Reed Army Medical Center, National Naval Medical Center, and Uniformed Services University of the Health Sciences, Bethesda, Maryland; [b] Reproductive Biology and Medicine Branch, National Institute of Child Health and Human Development, National Institutes of Health, Bethesda, Maryland; [c] Department of Obstetrics and Gynecology, Uniformed Services University of the Health Sciences, Bethesda, Maryland; [d] Reproductive Medicine Associates of Connecticut, Norwalk, Connecticut; and [e] Department of Radiology, Clinical Center, National Institutes of Health, Bethesda, Maryland

Objective: To evaluate whether persistence of pelvic pain after excision of endometriosis was associated with adenomyosis as defined by a thickened uterine junctional zone (JZ) on magnetic resonance (MR) imaging.
Design: Prospective clinical trial.
Setting: Government research hospital.
Patient(s): Fifty-three women with chronic pelvic pain.
Intervention(s): Preoperative MR imaging to measure uterine JZ thickness, surgical excision, and pathologic diagnosis of endometriosis. Those with biopsy-proven endometriosis were randomized to raloxifene or placebo. Visual analog scale (VAS) was used to rate dysmenorrhea and nonmenstrual pain severity before surgery and 3 months later.
Main Outcome Measure(s): Comparison of JZ thickness and pain severity before and 3 months after surgery in women with endometriosis controlling for medical treatment.
Result(s): Forty of the 53 patients had biopsy-proven endometriosis, and 6 of these 40 women with endometriosis had a thickened JZ. Overall, dysmenorrhea at 3 months was positively correlated with preoperative JZ thickness ($r = 0.47$, $P=.01$). Dysmenorrhea pain severity showed no significant decrease in those patients whose JZ measured ≥11 mm compared with those with JZ <8 mm ($P<.0001$; VAS decreased 4.3 ± 0.6), or ≥8 and <11 mm ($P<.02$; VAS decreased 4.8 ± 1.3). Nonmenstrual pain severity was correlated with JZ thickness ($r = 0.51$, $P=.004$) at 3 months with a significant decrease in nonmenstrual pain only in women with a JZ <8 mm (VAS decreased 4.0 ± 0.7, $P<.0001$). The association between dysmenorrhea and nonmenstrual pain reduction and thinner JZ remained after controlling for medical treatment.
Conclusion(s): Following surgical excision of endometriosis, chronic pelvic pain was significantly more likely to persist with JZ thickness >11mm on preoperative MR imaging. This suggests that myometrial JZ abnormalities or adenomyosis may contribute to chronic pelvic pain in women with endometriosis. (Fertil Steril® 2006;86: 711–5. ©2006 by American Society for Reproductive Medicine.)

Key Words: Adenomyosis, endometriosis, chronic pelvic pain, magnetic resonance imaging, junctional zone thickness, visual analog scale

Women with chronic pelvic pain present a diagnostic and therapeutic challenge. Chronic pelvic pain affects between 4% and 39% of women (1–3) and accounts for 10%–40% of all outpatient gynecologic visits (4). A quarter of women with chronic pelvic pain miss nearly 15 h of work per month, which accounts for a $14 billion loss in productivity per year (5, 6). The estimated combined cost of chronic pelvic pain owing to loss of productivity, diagnosis, medical, and surgical treatment is $39 billion per year (5, 6).

Endometriosis and adenomyosis are two commonly recognized causes of chronic pelvic pain. Endometriosis is symptomatic in 6%–10% of women in the general population (7–9) whereas adenomyosis has been diagnosed in

Received July 25, 2005; revised and accepted January 6, 2006.
Supported by the Intramural Research Program of the National Institute of Child Health and Human Development, National Institutes of Health, Bethesda, Maryland.
The opinions or assertions contained herein are the private views of the authors and are not to be construed as official or as reflecting the views of the Department of Health and Human Services, the Department of the Army or the Department of Defense.
Reprint requests: Pamela Stratton, M.D., RBMB/NICHD, National Institutes of Health, 10 Center Drive, BLDG 10 CRC, 1 E-3140, Bethesda, Maryland 20892-1109 (FAX: 301-480-6703; E-mail: ps79c@nih.gov).

0015-0282/06/$32.00
doi:10.1016/j.fertnstert.2006.01.030

Copyright ©2006 American Society for Reproductive Medicine, Published by Elsevier Inc.

8%–40% of women in unselected hysterectomy populations (10–15). Because both endometriosis and adenomyosis are caused by ectopic growth of endometriotic glands and stroma outside the endometrium, these disorders may coexist in up to 40% of patients (16). Thus, pelvic pain that is not responsive to surgical excision of endometriosis may be due to adenomyosis and may be difficult to treat without hysterectomy.

Adenomyosis is usually diagnosed by histologic evaluation of a hysterectomy specimen showing invasion of endometrial tissue into the myometrium. The smooth muscle bundles of the innermost myometrial layer are primarily parallel to the endometrium (17), and are comprised of closely packed muscle cells with an increased nuclear area and decreased intracellular matrix and water content (18). This junctional zone (JZ) has a different appearance on T2-weighted magnetic resonance (MR) imaging (19) and ultrasound from the rest of the myometrium. Thus, thickening of the JZ on these modalities appears to correlate well with the histologic diagnosis. As a result, ultrasound or MR imaging may aid in the nonsurgical diagnosis of adenomyosis, with MR imaging having a 78%–88% sensitivity and a 67%–93% specificity (15, 20–23).

In addition to a thickened JZ, the signs of adenomyosis on MR imaging include poor definition of the JZ borders, relative thickening of the JZ in a localized area, or the presence of high-signal foci within an area of low signal on T2-weighted sequences, which may represent cystically dilated endometrial glands, hemorrhage, or ectopic endometrium (23–25). Without an interpretation considering these subtleties, Reinhold et al. (23, 26) suggest that a JZ thickness ≥12 mm is significantly correlated with the accurate histologic diagnosis of adenomyosis whereas <8 mm is not.

In the present study, we hypothesized that women with chronic pelvic pain and histologically proven endometriosis also may have adenomyosis as diagnosed by a thickened JZ detected by MR imaging. We hypothesized that those women with adenomyosis would continue to have menstrual and nonmenstrual pain following the surgical excision of endometriosis.

MATERIALS AND METHODS

Fifty-three reproductive-aged women with chronic pelvic pain were enrolled consecutively in a prospective clinical trial that combined laparoscopic surgical excision of adhesions and endometriosis lesions with postoperative medical treatment. The Institutional Review Board of the National Institute of Child Health and Human Development approved the study. All women had a T2-weighted MR imaging scan before surgery to evaluate its potential in diagnosing endometriosis (27). The uterine JZ thickness was measured and classified into three categories: <8 mm, ≥8 to <11 mm, and ≥11 mm. For this

TABLE 1

Patient characteristics.

Characteristic	JZ Thickness Category <8 mm (n = 38)	≥8 to <11 mm (n = 9)	≥11 mm (n = 6)
Age[a] (years) (mean ± SE)	30.9 ± 1.1	33.8 ± 6.4	39.8 ± 3.5
BMI (mean ± SE)	27.2 ± 1.0	25.6 ± 2.0	22.8 ± 1.5
Gravida[a] (mean ± SE)	0.8 ± 0.2	0.9 ± 0.4	2.7 ± 1.1
Parity[a] (mean ± SE)	0.4 ± 0.1	0.7 ± 0.3	1.7 ± 0.7
Duration of pelvic pain (y) (mean ± SE)	11.1 ± 1.2	10.2 ± 2.6	11.2 ± 5.4
History of surgically diagnosed endometriosis, n (%)	26 (68.4)	8 (88.9)	5 (83.3)
Race, n (%)			
Black	5 (13.2)	2 (22.2)	2(33.3)
White	31 (81.6)	5 (55.6)	4 (66.7)
Hispanic	2 (5.3)	1 (11.1)	0 (0)
Asian	0 (0)	1 (11.1)	0 (0)
Endometriosis stage, n (%)			
0	6 (15.8)	1 (11.1)	0 (0)
I	11 (29.0)	2 (22.2)	3 (50.0)
II	12 (31.6)	3 (33.3)	2 (33.3)
III	5 (13.2)	1 (11.1)	1 (16.7)
IV	4 (10.5)	2 (22.2)	0 (0)

[a] $P<.05$

Parker. Pelvic pain after surgery may be adenomyosis. Fertil Steril 2006.

FIGURE 1

T2-weighted magnetic resonance images. (**A**) Sagittal T2-weighted MR image showing a retroverted uterus with a thick JZ with ill defined margins (*arrow*) consistent with adenomyosis. (**B**) Sagittal T2-weighted MR image of uterus showing an anteverted uterus with a normal low-signal-intensity JZ (*arrow*).

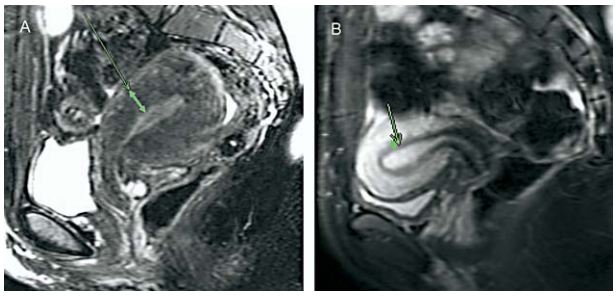

Parker. Pelvic pain after surgery may be adenomyosis. Fertil Steril 2006.

study, we considered a JZ thickness of ≥11 mm to be abnormal, because the radiographic abnormalities usually correlated with histologic confirmation of adenomyosis (26).

Surgeries used identical surgical techniques, in that all possible endometriosis lesions and endometriomas were excised using a contact neodinium-yttrium argon garnet laser and were sent for pathologic interpretation; adhesions were also lysed (27). Surgical findings were recorded at the time of surgery and categorized using the American Society of Reproductive Medicine (ASRM) classification system (28). The diagnosis of endometriosis was made if endometriosis was confirmed on at least one biopsy. Two to three weeks after surgery, only those with biopsy-proven endometriosis were randomized to 180 mg raloxifene or placebo, which was continued for 6 months.

Before surgery, all subjects were asked to rate dysmenorrhea and nonmenstrual pain severity by using a visual analog scale (VAS) from 0 (no pain) to 10 (most intense pain). Pain was reevaluated at 3 months only in those with endometriosis by repeating the VAS for dysmenorrhea and nonmenstrual pain.

Statistical Analysis

Frequency distributions describing demographic characteristics, history of surgical diagnosis of endometriosis and endometriosis stage at surgery for each JZ thickness group were compared by analysis of variance (ANOVA) or χ^2 tests depending on the type of variable. Paired *t* tests and repeated measures ANOVA were used to determine the relationship between each endometriosis patient's baseline and 3-month postoperative pain severity and her corresponding JZ thickness. Comparisons of JZ thickness and pain severity at baseline and at 3 months after surgery in those with endometriosis were determined by Pearson correlations. Repeated measures ANOVA was used to control for the interactions of medical treatment (raloxifene or placebo) and JZ thickness with the difference in pain severity at baseline and at 3 months. Changes in VAS scores are expressed as mean ± standard error. A *P* value of <.05 was considered to be statistically significant.

RESULTS

Women with a JZ ≥11 mm on MR imaging were significantly older and had more pregnancies and births than those with an intermediate JZ (≥8 to 11 mm) or JZ <8 mm. Other demographic characteristics and history did not differ (Table 1). Forty of 53 (75%) had biopsy-proven endometriosis. Six of these 40 subjects (15%) had a JZ ≥11 mm and therefore met the MR imaging criterion for the diagnosis of adenomyosis (Fig. 1). Thickened JZ possibly indicative of adenomyosis was only present in women with endometriosis (*P*=.32). The ASRM endometriosis stages for these six subjects were: three with stage I, two with stage II, and one with stage III.

Presurgical dysmenorrhea and nonmenstrual pain severity in subjects with endometriosis did not correlate with JZ thickness (Fig. 2).

When compared with baseline pain severity, dysmenorrhea was significantly decreased at 3 months for those

FIGURE 2

(**A**) Preoperative dysmenorrhea pain severity and JZ thickness in subjects with chronic pelvic pain. (**B**) Preoperative nonmenstrual pain severity and JZ thickness in subjects with chronic pelvic pain.

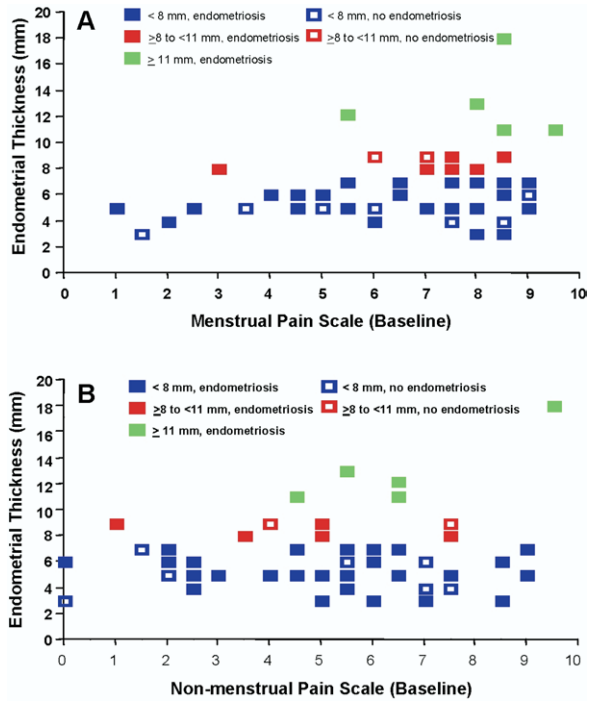

Parker. Pelvic pain after surgery may be adenomyosis. Fertil Steril 2006.

FIGURE 3

(**A**) Dysmenorrhea severity before and 3 months after surgery for women with endometriosis. Junctional zone thickness <8 mm: $P<.0001$, VAS decreased 4.3 ± 0.6; JZ thickness ≥8 and <11 mm: $P<.02$, VAS decreased 4.8 ± 1.3. (**B**) Nonmenstrual pain severity before and 3 months after surgery for women with endometriosis. Junctional zone thickness <8 mm: $P<.0001$, VAS decreased 4.0 ± 0.7.

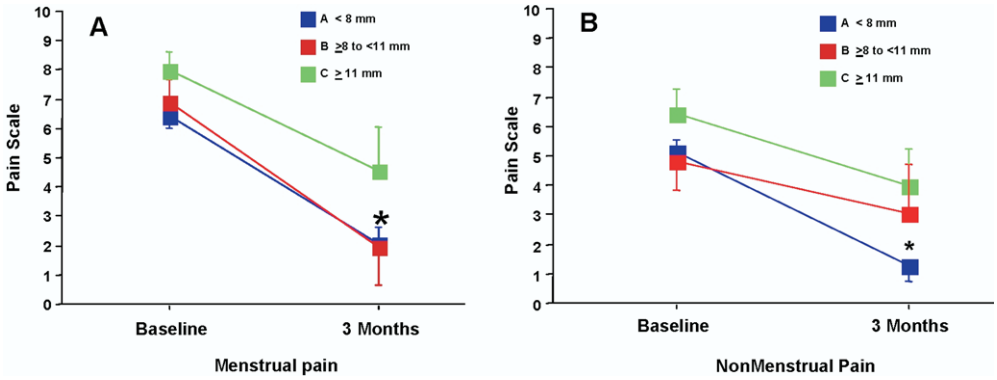

Parker. Pelvic pain after surgery may be adenomyosis. Fertil Steril 2006.

with endometriosis (VAS decreased 4.2 ± 0.6, $P<.0001$) (Fig. 3A) and was positively correlated with preoperative JZ thickness (r = 0.47, $P=.01$). The decrease in dysmenorrhea pain severity was associated with JZ thickness, with the greatest effect among those with JZ thickness <8 mm ($P<.0001$, VAS decreased 4.3 ± 0.6) than among those with JZ thickness ≥8 and <1 mm ($P<.02$, VAS decreased 4.8 ± 1.3) and no significant decrease in those with JZ thickness ≥11 mm. After controlling for treatment with raloxifene or placebo, decrease in dysmenorrhea remained associated with narrower preoperative JZ thickness.

Figure 3B illustrates the baseline and 3-month postoperative nonmenstrual pain severity by preoperative JZ thickness. As with dysmenorrhea pain severity, nonmenstrual pain severity was associated with greater JZ thickness (r = 0.51, $P=.004$). However, a significant decrease in nonmenstrual pain was observed only in those subjects with a JZ thickness <8 mm (VAS decreased 4.0 ± 0.7, $P<.0001$). As was seen with dysmenorrhea, after controlling for treatment with raloxifene or placebo, decrease in nonmenstrual pain remained associated with smaller preoperative JZ thickness.

DISCUSSION

We demonstrated that 15% of women with biopsy-proven endometriosis also had a JZ thickness ≥11 mm on MR imaging, likely indicative of adenomyosis, whereas women who had chronic pelvic pain without endometriosis did not, although this was not significant because of the small sample size. Increased JZ thickness did not seem to be associated with any particular ASRM endometriosis stage. Following surgical excision of endometriosis, nonmenstrual pelvic pain and dysmenorrhea were significantly more likely to persist with increasing JZ thickness, suggesting adenomyosis. Dysmenorrhea decreased significantly for those with a JZ thickness <11 mm; whereas nonmenstrual pain decreased significantly only in women with a JZ thickness <8 mm.

The innermost myometrium is structurally and functionally different from the outer myometrium (29). Because the smooth muscle bundles of the JZ are primarily parallel to the endometrium (17), this layer appears to play a significant role in modulating the propagation of myometrial contractions at different times in the menstrual cycle (30, 31). During ovulation, the contractions ascend from the cervix to the fundus, presumably aiding in sperm transport; whereas at menstruation, the contractions are initiated in the fundus and move toward the cervix, presumably aiding in the expulsion of menses (32).

Alterations in the muscular characteristics of the innermost myometrium, such as the thickness and fiber orientation, may alter the frequency, amplitude, and propagation of normal physiologic uterine contractions. In a cohort of women with endometriosis such as ours, abnormal JZ morphology and function might manifest as dyskinetic contractions. Such abnormal contractions might be experienced as dysmenorrhea or might enhance retrograde menstruation rather than the expulsion of menstrual effluent into the vagina, theoretically increasing the risk of endometriosis (32–34). It is also plausible that abnormal contractions could contribute to the pathogenesis of adenomyosis, by aiding in the invagination of endometrial cells into the myometrium.

We modified the categories described by Reinhold et al. (26), using a maximal JZ thickness of ≥11 mm rather than ≥12 mm to indicate adenomyosis and a JZ thickness of <8 mm rather than ≤8 mm to exclude the disease. Our rationale for slightly lowering the threshold for defining adenomyosis was that we saw potential signs of adenomyosis usually noted in those with a JZ thickness between 8 and 12 mm.

These include focal or diffuse thickening of the uterine JZ, poor definition of the JZ borders, the presence of a low-signal-intensity myometrial mass, or the presence of high-signal foci within an area of low signal on T2-weighted sequences which may represent cystically dilated endometrial glands, hemorrhage, or ectopic endometrium (23–25). These abnormal areas of low signal correlate well with myoproliferative changes seen with adenomyosis (25). Despite this modification, we had a small number of subjects with a JZ thickness greater than 11 mm.

Strengths of the study include the preoperative MR imaging before a standardized surgery in which all evidence of endometriosis was removed and, we believe, the surgical treatment of endometriosis-related pain was optimized. Endometriosis was diagnosed histologically for all patients. We also obtained pain VAS regarding menstrual and nonmenstrual pain before surgery and 3 months later. A weakness of the study is that we did not perform hysterectomy in any of our subjects to confirm the presence of adenomyosis. Additionally, no MR images were obtained at the 3 month time point to assess persistence of a JZ abnormality, although we would not expect this abnormality to decrease over time.

In summary, women with endometriosis also may have myometrial JZ abnormalities, possibly indicative of adenomyosis that contributes significantly to chronic pelvic pain. In women without significant decrease in pain after radical surgical excision of endometriosis, MR imaging evaluation for the JZ measurement and diagnosis of adenomyosis should be considered.

Acknowledgements: The authors thank Ms. Nancy Kim for assistance with the database and editing the figures and Victoria Shanmugan, M.D., for creating and Pat Moyer, Ph.D., for computerizing the pelvic pain form.

REFERENCES

1. Jamieson DJ, Steege JF. The prevalence of dysmenorrhea, dyspareunia, pelvic pain, and irritable bowel syndrome in primary care practices. Obstet Gynecol 1996;87:55–8.
2. Zondervan KT, Yudkin PL, Vessey MP, Dawes MG, Barlow DH, Kennedy SH. Prevalence and incidence of chronic pelvic pain in primary care: evidence from a national general practice database. Br J Obstet Gynaecol 1999;106:1149–55.
3. Mathias SD, Kuppermann M, Liberman RF, Lipschutz RC, Steege JF. Chronic pelvic pain: prevalence, health-related quality of life, and economic correlates. Obstet Gynecol 1996;87:321–7.
4. Harris RD, Holtzman SR, Poppe AM. Clinical outcome in female patients with pelvic pain and normal pelvic US findings. Radiology 2000;216:440–3.
5. Chronic pelvic pain: an integrated approach. Educational Series on Women's Health Issues. Washington (DC): Association of Professors of Gynecology and Obstetrics; 2000.
6. Wenof M. Chronic pelvic pain: a patient education booklet. Birmingham (AL): International Pelvic Pain Society; 1999:1–11.
7. Eskenazi B, Warner ML. Epidemiology of endometriosis. Obstet Gynecol Clin North Am 1997;24:235–58.
8. Olive DL, Pritts EA. Treatment of endometriosis. N Engl J Med 2001:345:266–75.
9. Olive DL, Pritts EA. The treatment of endometriosis: a review of the evidence. Ann NY Acad Sci 2002;955:360–72; discussion 389–93, 396–406.
10. Owolabi TO, Strickler RC. Adenomyosis: a neglected diagnosis. Obstet Gynecol, 1977;50:424–7.
11. Bird CC, McElin TW, Manalo-Estrella P. The elusive adenomyosis of the uterus—revisited. Am J Obstet Gynecol 1972;112:583–93.
12. Molitor JJ. Adenomyosis: a clinical and pathological appraisal. Am J Obstet Gynecol 1971;110:275–84.
13. Bergholt T, Eriksen L, Berendt N, Jacobsen M, Hertz JB. Prevalence and risk factors of adenomyosis at hysterectomy. Hum Reprod 2001: 16:2418–21.
14. Siegler AM, Camilien L. Adenomyosis. J Reprod Med 1994;39: 841–53.
15. Atri M, Reinhold C, Mehio AR, Chapman WB, Bret PM. Adenomyosis: US features with histologic correlation in an in-vitro study. Radiology 2000;215:783–90.
16. Berek J, Hillard P. Novak's gynecology. 13th ed. Baltimore (MD): Lippincott Williams & Wilkins; 2002.
17. Brown HK, Stoll BS, Nicosia SV, Fiorica JV, Hambley PS, Clarke LP, et al. Uterine junctional zone: correlation between histologic findings and MR imaging. Radiology 1991;179:409–13.
18. Scoutt LM, Flynn SD, Luthringer DJ, McCauley TR, McCarthy SM. Junctional zone of the uterus: correlation of MR imaging and histologic examination of hysterectomy specimens. Radiology 1991;179:403–7.
19. Hricak H, Alpers C, Crooks LE, Sheldon PE. Magnetic resonance imaging of the female pelvis: initial experience. AJR Am J Roentgenol 1983;141:1119–28.
20. Dueholm M, Lundorf E, Hansen ES, Sorensen JS, Ledertoug S, Olesen F. Magnetic resonance imaging and transvaginal ultrasonography for the diagnosis of adenomyosis. Fertil Steril 2001;76:588–94.
21. Bazot M, Cortez A, Darai E, Rouger J, Chopier J, Antoine JM, et al. Ultrasonography compared with magnetic resonance imaging for the diagnosis of adenomyosis: correlation with histopathology. Hum Reprod 2001;16:2427–33.
22. Ascher SM, Arnold LL, Patt RH, Schruefer JJ, Bagley AS, Semelka RC, et al. Adenomyosis: prospective comparison of MR imaging and transvaginal sonography. Radiology 1994;190:803–6.
23. Reinhold C, McCarthy S, Bret PM, Mehio A, Atri M, Zakarian R, et al. Diffuse adenomyosis: comparison of endovaginal US and MR imaging with histopathologic correlation. Radiology 1996;199:151–8.
24. Togashi K, Nishimura K, Itoh K, Fujisawa I, Noma S, Kanaoka M, et al. Adenomyosis: diagnosis with MR imaging. Radiology 1988;166: 111–4.
25. Togashi K, Ozasa H, Konishi I, Itoh H, Nishimura K, Fujisawa I, et al. Enlarged uterus: differentiation between adenomyosis and leiomyoma with MR imaging. Radiology 1989;171:531–4.
26. Reinhold C, Tafazoli F, Wang L. Imaging features of adenomyosis. Hum Reprod Update 1998;4:337–49.
27. Stratton P, Winkel CA, Sinaii N, Merino MJ, Zimmer C, Nieman LK. Location, color, size, depth, and volume may predict endometriosis in lesions resected at surgery. Fertil Steril 2002;78:743–9.
28. Revised American Society for Reproductive Medicine classification of endometriosis: 1996. Fertil Steril 1997;67:817–21.
29. Brosens JJ, Barker FG, de Souza NM. Myometrial zonal differentiation and uterine junctional zone hyperplasia in the nonpregnant uterus. Hum Reprod Update 1998;4:496–502.
30. Lesny P, Killick SR. The junctional zone of the uterus and its contractions. BJOG 2004;111:1182–9.
31. Brosens JJ, de Souza NM, Barker FG. Uterine junctional zone: function and disease. Lancet 1995;346:558–60.
32. Ijland MM, Evers JL, Dunselman GA, van Katwijk C, Lo CR, Hoogland HJ. Endometrial wavelike movements during the menstrual cycle. Fertil Steril 1996;65:746–9.
33. Salamanca A, Beltran E. Subendometrial contractility in menstrual phase visualized by transvaginal sonography in patients with endometriosis. Fertil Steril 1995;64:193–5.
34. Leyendecker G, Kunz G, Wildt L, Beil D, Deininger H. Uterine hyperperistalsis and dysperistalsis as dysfunctions of the mechanism of rapid sperm transport in patients with endometriosis and infertility. Hum Reprod 1996;11:1542–51.